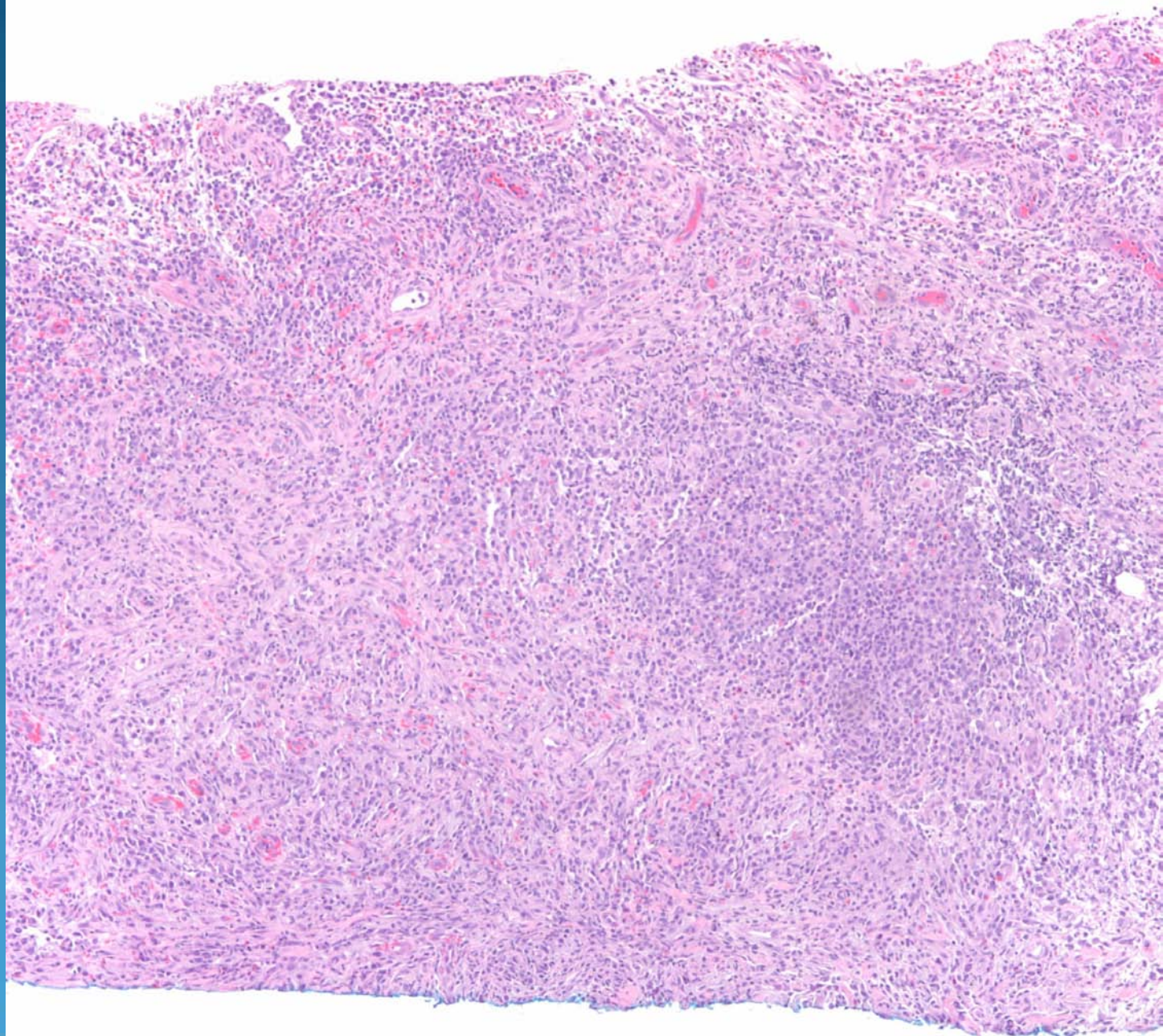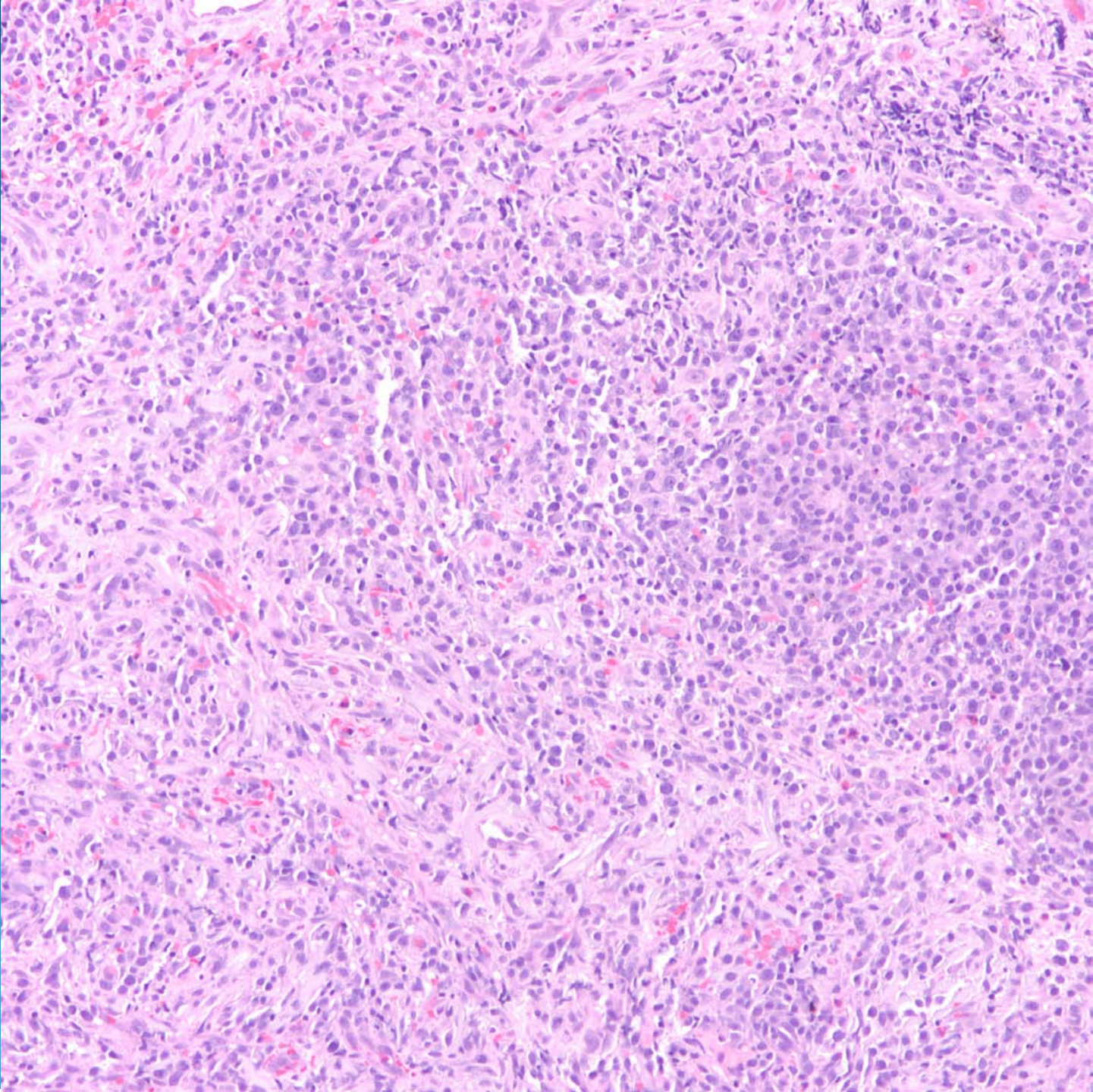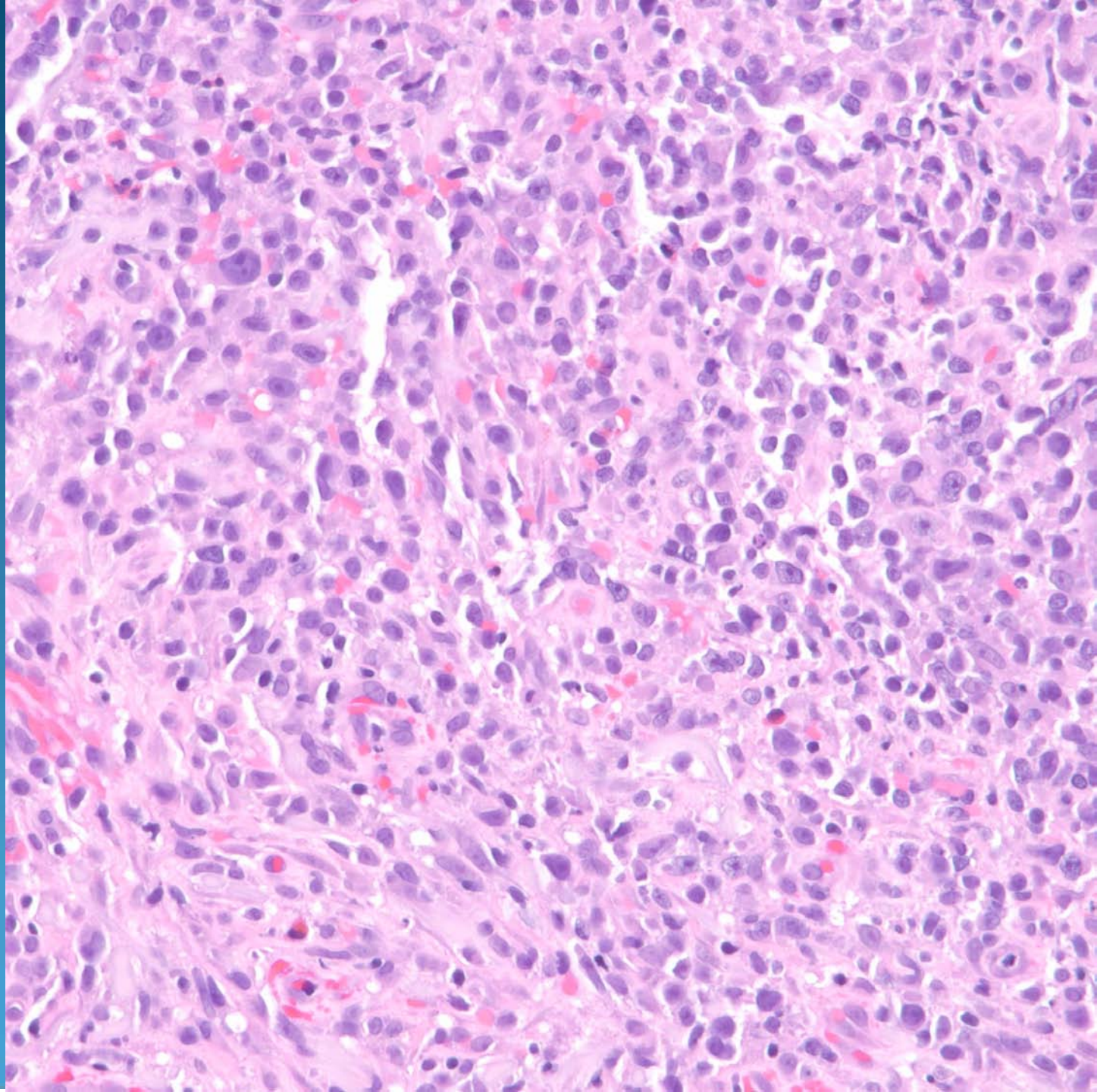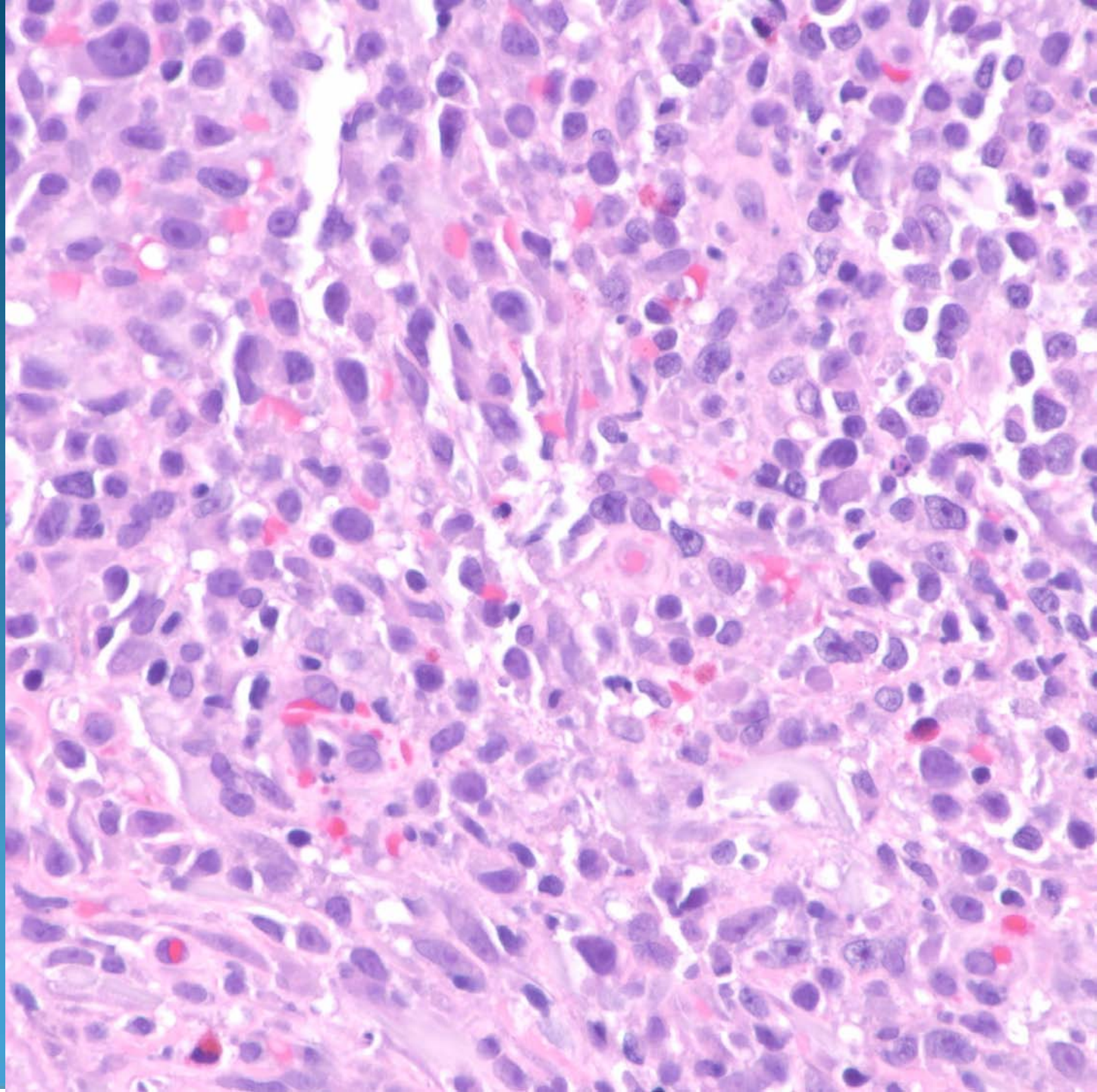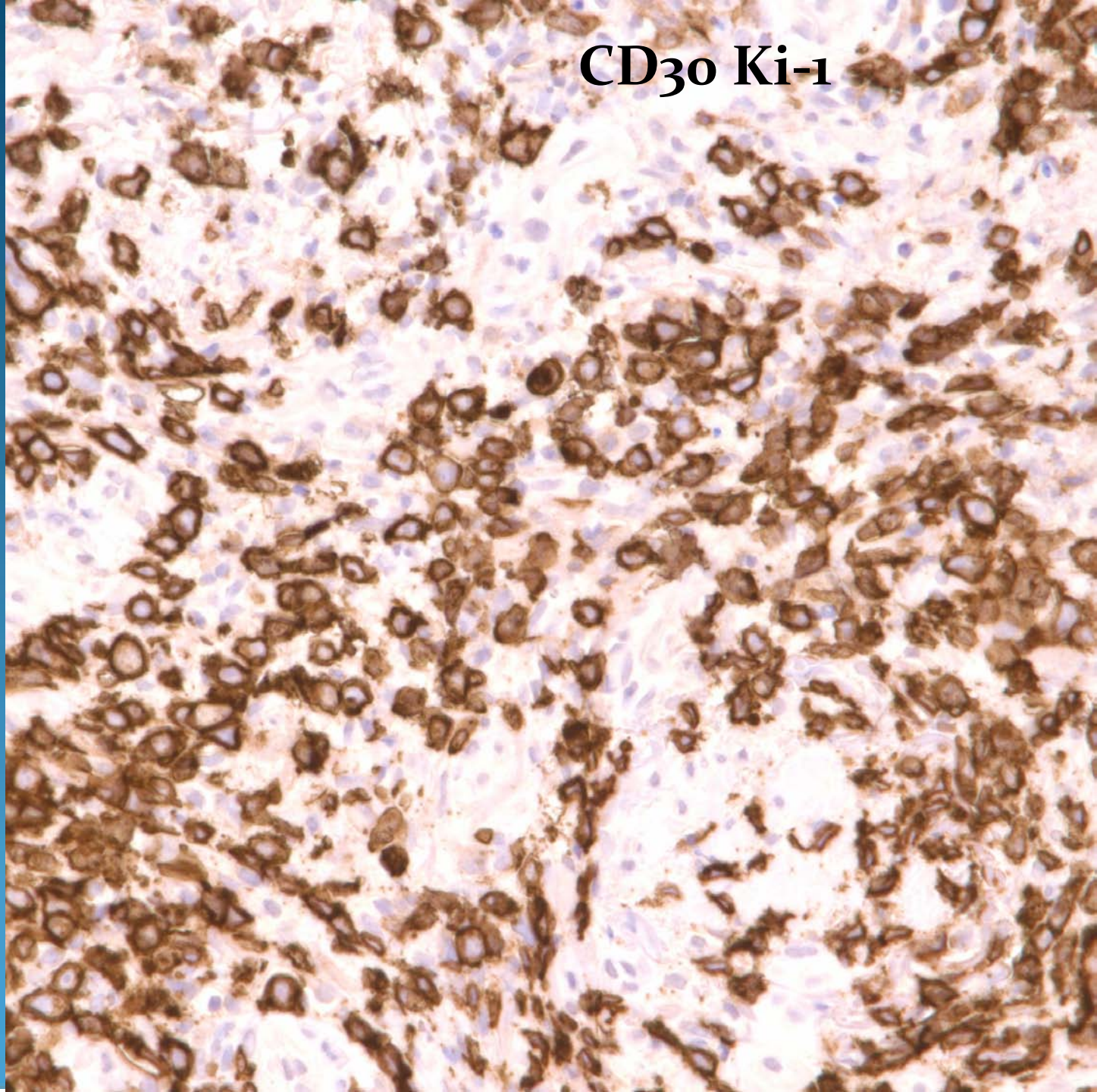


# Anaplastic Large Cell Lymphoma- CD30+

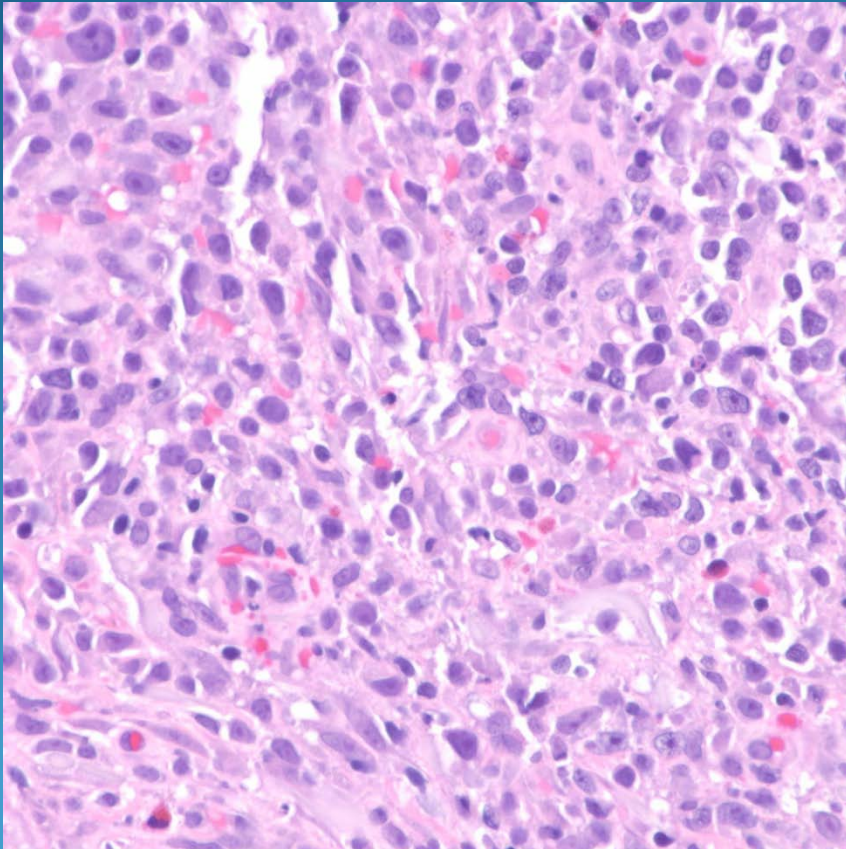


CD30 Ki-1





# Pearls



- Pleomorphic mononuclear cell infiltrate with enlarged and hyperchromatic nuclei with prominent nucleoli and numerous MF
- May have mixed inflammatory cell infiltrate
- Confirm with IHC-CD30+
- Rule out systemic anaplastic lymphoma metastatic to the skin